

Arrested eruption of the permanent lower second molar

Henriette Vedtofte*, J. O. Andreasen** and Inger Kjær*

*Department of Orthodontics, School of Dentistry, University of Copenhagen and

**Department of Oral & Maxillofacial Surgery, Copenhagen University Hospital (Rigshospitalet), Denmark

SUMMARY The incidence of retention/impaction of the permanent lower second molar (M_2 inf) lies between 0.6/1000 and 3/1000. Therefore, the purpose of the present study was to investigate the craniofacial morphology, the frequency of dental anomalies and the inclination of the affected M_2 inf and the adjacent first molar in patients with arrested eruption of M_2 inf. The overall goal was to elucidate the aetiology of arrested tooth eruption and to present the characteristics of these patients in order to improve diagnosis and treatment planning.

Radiographic material (profile radiographs and orthopantomograms) from 19 patients (nine females and 10 males; 13–19 years of age at the time of referral) were analysed. The ages of the patients when profile radiographs were taken for cephalometric analysis varied from 8 to 16 years.

The study shows that this group of patients, compared with a reference group, had an increased sagittal jaw relationship (Class II). Specifically, the mandibular prognathism was less, the mandibular gonial angle smaller, the mandibular alveolar prognathism enlarged and the maxillary incisor inclination less than in the reference group.

Furthermore, this group of patients had a more frequent occurrence of morphological tooth anomalies, such as root deflections, invaginations, and taurodontism. However, none of the patients with arrested eruption of M_2 inf had agenesis of the lower third molar. The study did not reveal an association between the degree of inclination of the M_2 inf and that of the first molar in the same region.

The results of this investigation show that conditions such as the craniofacial morphology and deviations in the dentition are associated with arrested eruption of M_2 inf. Therefore, it is important to evaluate these conditions in future diagnosis and treatment planning of patients with arrested eruption of M_2 inf.

Introduction

It is important to diagnose arrested eruption of the permanent lower second molar (M_2 inf) as early as possible, since treatment at a late stage can be complicated and present a difficult clinical problem.

Seemingly, a small group of patients presents with arrested eruption of permanent molars without any apparent relationship to systemic diseases or local physical obstacles to eruption. The incidence of retention/impaction of M_2 inf lies between 0.6/1000 (Grover and Lorton, 1985) and 3/1000 (Johnsen, 1977). Apart from case

reports, only a few studies have been published in this field (Evans, 1988; Varpio and Wellfelt, 1988; Wellfelt and Varpio, 1988; Raghoobar *et al.*, 1989, 1992; Philipsen *et al.*, 1992).

Evans (1988) showed that in the UK there had been an increase in the incidence of impacted/retained M_2 inf from 1976 to 1986. An association was demonstrated between impaction of M_2 inf and the occurrence of crowding in the lower jaw and the degree of mesial inclination of the impacted molar. Even though there was a marked decrease over the same period in early loss of primary teeth and in the destruction of primary molars, these factors were not found to

contribute directly to clarifying the aetiology of impaction of M_2 inf.

Varpio and Wellfelt (1988) showed that nearly all patients with impacted M_2 inf had a third molar anlage and the retention was related to crowding in the molar region. They found bilateral malposition of M_2 inf in 23 per cent, and that there was a predominance of impaction on the right side. Most of the impacted teeth were in a mesio-angular position, but in approximately 25 per cent a vertical position of the tooth and other anomalies were seen. In that study, impaction of M_2 inf was observed most frequently in males. Their conclusion was that lack of space was the cause of retention of M_2 inf molar in the mesio- and disto-angular positions, whereas local factors, for instance ankylosis which can be difficult to diagnose, were the reason for retention in a vertical position. Wellfelt and Varpio (1988) evaluated possible treatment methods and results, concluding that denudation is often the only treatment. The treatment of mesially inclined molars was the most successful, and it was not always necessary to extract the third molar. The treatment of partially retained, distally inclined M_2 inf showed the poorest prognosis, and the inclination was not improved by extraction of the third molar. Molars in a vertical position were considered to be ankylosed.

Raghoobar *et al.* (1989) examined 26 secondarily retained M_2 inf histologically and found that all of them had ankylosed regions which could not clinically be diagnosed with certainty (percussion sound, radiography). It is still not clear, though, whether the state of ankylosis was a result of arrested eruption or if it was the primary cause resulting in arrested eruption.

Philipsen *et al.* (1992) showed, in a histological study, that in the gingiva which covered the retained M_1 and M_2 , the occurrence of classical odontogenic tumours could be diagnosed in 24.3 per cent. In 29.7 per cent they found a condition of hamartomatous character, not previously described, which they termed 'odontogenic giant cell fibromatosis'. In the remaining 45.9 per cent there were no histomorphological changes. The odontogenic tumours were associated more often with arrested eruption of the first molar than of the second molar (ratio 8:1), and 'odontogenic

giant cell fibromatosis' occurred most frequently in the mandible (M_1 inf and M_2 inf). In that study it was stated that the overlying gingiva in some patients contained areas that could be diagnosed histologically as odontogenic tumours or as 'odontogenic giant cell fibromatosis'.

Only a few studies of arrested eruption of M_2 inf have been published, probably because of the rarity of its occurrence. Under normal conditions an association exists between the eruption of the teeth and growth of the jaws (Björk, 1969; Björk and Skieller, 1972, 1983). A former study has also shown that arrest of tooth formation and tooth eruption occur in association with deviations in tooth morphology (Bang *et al.*, 1995).

The purpose of the present study was to clarify the aetiological aspects of arrested eruption of the permanent lower second molar. The aims were to investigate:

1. Whether there was an association between arrested eruption of M_2 inf and the craniofacial morphology. This is a relationship which has not previously been studied.
2. Whether there was an association between arrested eruption of M_2 inf and local or general anomalies of the dentition. This aspect has also not previously been investigated.
3. Whether there was an association between the inclination of M_1 inf and the inclination of M_2 inf.

Materials and methods

Material

The material for this study consisted of selected radiographs of patients who had been referred for surgical treatment of delayed eruption of M_2 inf, either to the Department of Oral and Maxillofacial Surgery of the Copenhagen University Hospital or to the Department of Oral and Maxillofacial Surgery at the Copenhagen School of Dentistry during the period 1984–1991.

The selection criterion for the patients was arrested eruption of M_2 inf, defined as the M_2 inf not having erupted at the time when more than two-thirds of the root was formed and when the permanent second molars in the maxilla were fully erupted.

Table 1 (a) Age distribution at time of referral.

	<i>n</i>	Mean	SD	Min.	Max.
Girls	9	15 ⁴	1 ⁹	13 ³	19 ⁴
Boys	10	15 ³	1 ⁴	13 ⁷	17 ⁵
Total	19	15 ³	1 ⁶	13 ³	19 ⁴

(b) Age distribution when profile radiographs were taken.

	<i>n</i>	Mean	SD	Min.	Max.
Girls	9	12 ⁷	2 ⁸	10 ²	16 ²
Boys	10	13	1 ⁸	8 ⁷	14 ¹
Total	19	12 ⁹	2 ²	8 ⁷	16 ²

For the patients to be included in the study, a lateral cephalogram, taken in a cephalostat, as well as an orthopantomogram had to be available.

Of the original selected material of 50 patients, only 19 met the above-mentioned criteria. The reason for most of the exclusions was lack of lateral cephalograms. The sex distribution was nine females and 10 males, with a total of 21 retained M₂inf. The ages of the patients at the time of referral varied from 13 years 3 months to 19 years 4 months (Table 1a), and the patients' ages at the time the profile radiograph was taken varied from 8 years 7 months to 16 years 2 months (Table 1b).

Methods

Cephalometric method. Twenty-seven reference points were marked directly on the profile radiographs and then digitized with the aid of the TIOPS® computer program (TIOPS Aps, Algade 12, DK-4000 Roskilde, Denmark). Seventeen angular measurements (Table 2, Figure 1) were calculated according to Björk (1960).

The statistical analysis was performed using the SAS® statistical package 1988 (SAS Institute Inc. 1988 SAS/STAT™ User's guide, Release 6.03 Edition. SAS Institute Inc., Cary, NC).

Each variable in the study group was tested by Student's *t*-test, but no significant sexual

Table 2 List of cephalometric variables according to Björk (1960).

1.	n-s-ar	Angulation of cranial base
2.	n-s-ba	Angulation of cranial base
3.	ML/RL	Mandibular jaw angle
4.	s-n-ss	Maxillary prognathism
5.	s-n-pg	Mandibular prognathism
6.	s-n-sm	Mandibular prognathism
7.	ss-n-pg	Sagittal jaw relationship
8.	ss-n-sm	Sagittal jaw relationship
9.	NSL/NL	Maxillary inclination
10.	NSL/NL	Mandibular inclination
11.	NL/ML	Vertical jaw relationship
12.	pr-n-ss	Maxillary alveolar prognathism
13.	IL _s /NL	Maxillary incisor inclination
14.	IL _i /ML	Mandibular incisor inclination
15.	CL/ML	Mandibular alveolar prognathism
16.	OL _s /NL	Maxillary zone
17.	OL _i /ML	Mandibular zone

ML, the mandibular line, tangent to the base of the mandibular corpus through gn; RL, the ramus line tangent to the posterior margin of the mandibular ramus through ar; NSL, the nasion-sella line through n and s; NL, the nasal line through sp and pm; IL_s, the long axis through the upper incisors from the incisal point to the apex; IL_i, the long axis through the lower incisors from the incisal point to the apex; CL, the chin line, tangent to the mental prominence through id; OL_s, the superior occlusal line from the incisal point to the distobuccal cusp of M₁sup; OL_i, the inferior occlusal line from the incisal point to the distobuccal cusp of M₁inf.

dimorphism was found. Similarly, the analysis of variance regarding age showed no significant differences. The patients were therefore pooled and their mean facial morphology was compared with a known reference group consisting of mean values for 12- and 20-year-old Swedish youths (Björk, 1947, 1960).

The difference in the mean was assessed by Student's *t*-test and *t*-values were calculated. The levels of significance were set at 5, 1, and 0.1 per cent, indicated by 1, 2, or 3 asterisks.

The method error *S(i)* was calculated by repeating the registration of variables on the radiographs at approximately monthly intervals for the entire patient material. No significant differences were found between the two series of recordings (Table 3).

Registration of dental anomalies. Anomalies of the retained M₂inf and of the dentition in general

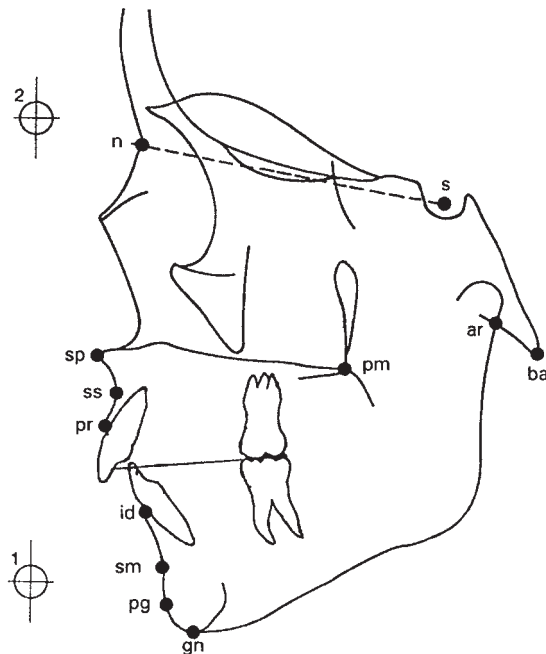


Figure 1 Diagram of contours and cephalometric landmarks used in the cephalometric evaluation of a lateral cephalogram, according to Björk (1960).

were evaluated qualitatively on orthopantomograms and intra-oral radiographs of each individual included in the study. The material was examined twice by two investigators. Only

observations on which there was agreement were recorded. The following deviations from the normal dental morphology were recorded:

Crown morphology

1. Crown size: a large tooth crown was noted if there was a distinct difference in the size of the crowns bilaterally.
2. Crown shape: invagination in the upper front, determined radiographically by a distinct enamel outline or filling at the site of the dental tubercle.

Root morphology

3. Root length: a short root was noted when the crown/root ratio was maximum 1:1.5 (or when the root was clearly shorter than that of the contralateral tooth).
4. Root shape: root deflection, when there was a distinct mesial or distal deflection of the root.

Tauro-, meso-, or hyper-taurodontism in accordance with the criteria described by Schulze (1987).

Long, gracile roots (Kjær, 1995).

In addition to these, other deviations were recorded as follows: ankylosis, agenesis, retention, internal resorption and osteoma.

Table 3 Statistical data for the study group.

Variable	<i>n</i>	Min.	Max.	Mean	SD	SE	<i>S(i)</i>
n-s-ar	19	114.63	131.81	122.40	4.89	1.12	0.19
n-s-ba	19	125.02	139.41	131.26	4.20	0.96	0.17
ML/RL	19	114.89	135.32	122.40	5.10	1.19	0.25
s-n-ss	19	78.00	88.66	82.39	2.52	0.58	0.14
s-n-pg	19	74.80	85.54	78.67	2.55	0.59	0.07
s-n-sm	19	73.92	84.91	77.85	2.57	0.59	0.10
ss-n-pg	19	0.00	7.87	3.73	2.08	0.48	0.12
ss-n-sm	19	1.02	7.40	4.54	1.76	0.40	0.13
NSL/NL	19	-3.36	12.20	6.40	3.83	0.88	0.20
NSL/ML	19	25.05	40.56	31.37	4.46	1.02	0.20
NL/ML	19	12.85	32.55	24.98	4.81	1.10	0.25
pr-n-ss	19	-0.47	4.33	2.28	1.16	0.27	0.13
IL _s /NL	19	87.03	118.64	106.08	7.56	1.73	0.62
IL _s /ML	19	83.21	107.62	95.53	7.20	1.65	0.49
CL/ML	19	57.81	85.43	73.59	5.98	1.37	0.24
OL _s /NL	19	6.61	20.28	11.83	4.04	0.93	0.51
OL _s /ML	19	13.90	23.49	19.10	2.64	0.61	0.41

Registration of inclination of M_{2inf} . The inclination of the retained M_{2inf} in relation to that of the first permanent molar on the same side was measured on the orthopantomograms as described by Evans (1988). From the tangent to the tips of the cusps, a perpendicular line was constructed through the middle of the crown and root on the affected M_{2inf} , and on the adjacent M_{1inf} (Figure 2). The angle between these lines was measured twice and the mean of the two measurements was used to assess the inclination. Angles greater than 40 degrees were assigned *mesial inclination*, between 40 and -20 degrees *vertical position*, and less than -20 degrees *distal inclination*.

Results

Craniofacial morphology

The results of the morphological analysis of the study group compared with the reference group are shown in Table 4. The mandibular jaw angle




Figure 2 Diagram of the measurement of the angle between the inclination of M_{2inf} and the first molar in the same region. The angle indicates the inclination of M_{2inf} .

Table 4 Comparison of the facial morphology of the study group with the reference group.

Study group ($n = 19$)			Reference group ¹ (estimated $n = 243$)		Differences (mean) Study group – reference group
Variable	Mean	SD	Mean	SD	
n-s-ar	122.4	4.89	124	5	-1.6
n-s-ba	131.26	4.2	131	4.5	0.26
ML/RL	122.4	5.1	126	6	-3.6**
s-n-ss	82.39	2.52	82	3.5	0.39
s-n-pg	78.67	2.55	80	3.5	-1.33*
s-n-sm	77.85	2.57	79	3.5	-1.15
ss-n-pg	3.73	2.08	2	2.5	1.73**
ss-n-sm	4.54	1.76	3	2.5	1.54**
NSL/NL	6.40	3.83	8	3	-1.6
NSL/ML	31.37	4.46	33	6	-1.63
NL/ML	24.98	4.81	25	6	-0.02
pr-n-ss	2.28	1.16	2	1	0.28
IL _s /NL	106.08	7.56	110	6	-3.92*
IL _s /ML	95.53	7.2	94	7	1.53
CL/ML	73.59	5.98	70	6	3.59*
OL _s /NL	11.83	4.04	10	4	1.88
OL _s /ML	19.1	2.64	20	5	-0.9

¹Björk, 1960.

* $P \leq 0.05$; ** $P \leq 0.01$.

Table 5 Dental anomalies.

Anomaly	Dentition in general (number of patients 19)			Retained M ₂ inf (number of teeth 21)		
	<i>n</i>	%	Reference values	<i>n</i>	%	Reference values
Large crown (same side as retained M ₂ inf)	1	5	–	2	10	–
Invagination upper front	7	37	3–10% ¹			
Short root shape	2	10	–			
Root deflection	11	58	–	6	29	–
Root deflection upper premolars	7	37	11.8% ²			
Taurodontism M ₂ sup	7	37	1.4–5.8% ³	2	10	1.4–5.8% ³
Long, gracile roots	5	26	–			
Ankylosis				3	14	–
Agenesis maxillary second premolars	1	5	2.2–3.4% ⁴			
Retention right maxillary canine	1	5	–			
Internal resorption				1	5	–
Osteoma	1	5	–			
Agenesis M ₃ inf	0	0	22.5–36.6% ⁵			

¹Gorlin and Goldman, 1970.²Schulze, 1987.³Schulze, 1987.⁴Gorlin and Goldman, 1970.⁵Gorlin and Goldman, 1970.

(ML/RL) in the study group was 3.6 degrees smaller and differed significantly from the reference group ($P < 0.01$). The mandibular prognathism (s–n–pg) was 1.33 degrees less ($P < 0.05$) in the study group than in the reference group. The sagittal jaw relationship (ss–n–sm) in the study group was on average significantly different from the reference group: 1.54 degrees greater ($P < 0.01$) (Class II). The upper incisor inclination (ILs/NL) was significantly less in the study group than in the reference group: 3.92 degrees ($P < 0.05$). The mandibular alveolar prognathism (CL/ML) was 3.59 degrees greater ($P < 0.05$) in the study group than in the reference group. There were no significant differences in the other variables studied.

Dental anomalies

The number of anomalies in dental morphology in the dentition and anomalies in the morphology of the M₂inf with arrested eruption in the study group are summarized in Table 5 and illustrated in Figures 4–7. Taurodontism of the

permanent upper second molars was observed in seven patients (37 per cent of all patients) and of M₂inf with arrested eruption in two patients. Deviant root morphology was registered in seven patients, in the form of long, gracile roots in five patients, and short root shape in two subjects. Root deflections were recorded on other teeth in the dentition in 11 patients (58 per cent), and on six M₂inf with arrested eruption. In seven patients (37 per cent) invaginations in the upper anterior incisors could be demonstrated. The crown size was larger in three patients, two of these crowns being on M₂inf with arrested eruption.

In addition to the above deviations, radiographic signs of ankylosis were registered on three of the M₂inf with arrested eruption, and internal resorption on one M₂inf with arrested eruption. Moreover, osteoma was registered in one patient, agenesis of maxillary second premolars in one patient, and retention of a right maxillary canine in one patient. In none of the patients in the study group was agenesis of the permanent lower third molar observed.

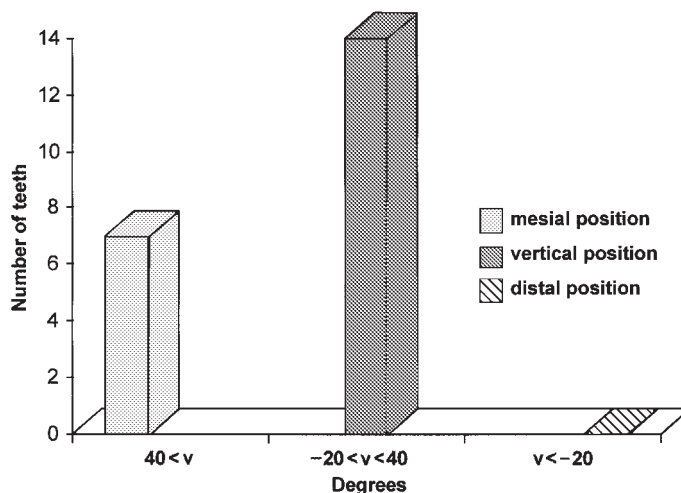


Figure 3 Inclination of retained M_{2inf} .

Inclination of M_{2inf}

None of the molars with arrested eruption were distally inclined. Seven teeth were positioned with a mesial inclination and 14 teeth were positioned vertically. Figure 3 shows the occurrence of the different inclinations of M_{2inf} with arrested eruption in relation to the inclination of the permanent first molar on the same side.

Orthopantomograms from the sample studied, showing arrested eruption of M_{2inf} and examples

of dental anomalies and type of M_{2inf} inclinations, are demonstrated in Figures 4–7.

Discussion

This study shows that an association exists between craniofacial morphology and the occurrence of arrested eruption of M_{2inf} .

The method error was assessed by double measurement of all profile radiographs and no

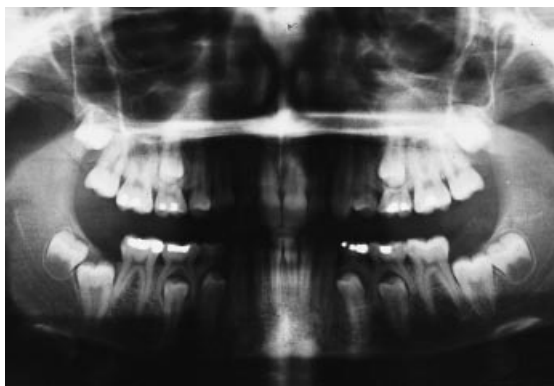


Figure 4 Orthopantomogram of a girl aged 15 years with arrested eruption of lower second molars. Taurodontic root forms are seen on all second molars.

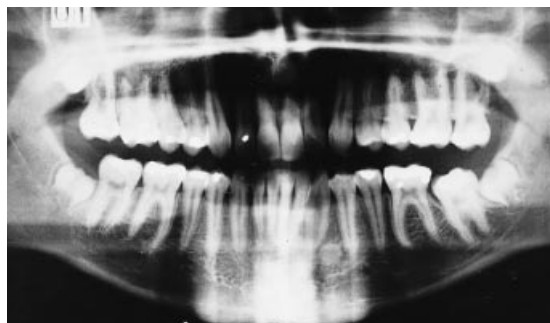


Figure 5 Orthopantomogram of a boy aged 17 years 8 months with arrested eruption of the lower right second molar. Signs of ankylosis are seen on lower right second molar. Invaginations can also be seen in the maxillary front and root deflection on upper right first premolar, as well as osteoma in the region of lower right canine and first premolar.

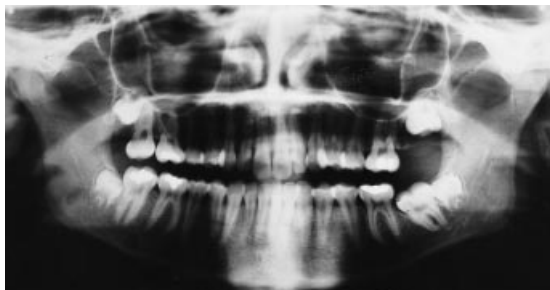


Figure 6 Orthopantomogram of a girl aged 15 years 1 month with arrested eruption of the lower right second molar. Taurodontism of upper left second molar is seen and a tendency to thin gracile roots generally in the dentition.

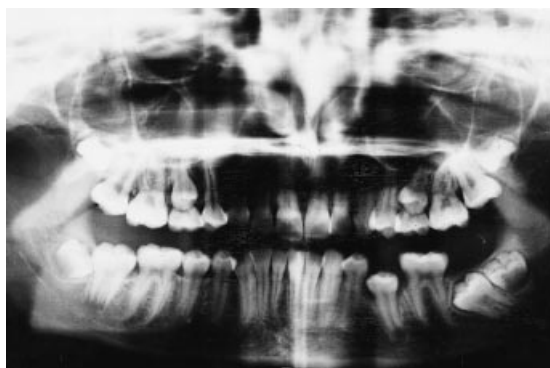

Figure 7 Orthopantomogram of a girl aged 13 years 9 months with arrested eruption of the lower right second molar. Taurodontic root forms are seen on the second molars in the maxilla.

systematic errors were revealed by the final measurement. The magnitude of the $S(i)$ values was in agreement with previous studies (Solow, 1966; Blok, 1991; Nodal *et al.*, 1994). The cephalometric variables showed large variability in the study group. This is presumably because most of the patients who participated in the study were orthodontic patients with major deviations in craniofacial morphology.

Patients with arrested eruption of M_2inf had in general an increased sagittal jaw relationship (Class II) compared with the reference group. The incisal maxillary inclination in the study group was less than in the reference group. It is remarkable that the mandibular jaw angle was smaller in the study group than in the reference

group, and that the mandibular alveolar prognathism was greater in the study group than in the reference group. According to Björk (1969), and Björk and Skieller (1972, 1983), these are the important signs seen in patients with a vertically directed condylar growth, in which the entire mandibular dentition erupts in an anterior direction.

Even though the patient material on which this investigation has been conducted is small, the study suggests that patients with arrested eruption of M_2inf have a characteristic craniofacial morphology which ought to be taken into account for treatment purposes.

Furthermore, it should be mentioned that the reference group employed in this investigation was selected on the basis of ethnic (Nordic) and age criteria. Ideally, a control group should be chosen at random among children without an orthodontic treatment indication and the control group should be studied by the same method as the study group, but ethical considerations do not allow this.

In most of the patients in the study group dental morphological anomalies were registered. The assessment of the occurrence of these anomalies must be regarded with caution. It is known from other studies that some of the registrations, for example, the assessment of root length, call for standardized radiographic technique and knowledge of the normal crown/root ratio (Lind, 1972; Jakobsson and Lind, 1973; Andreasen and Andreasen, 1985). In the present retrospective study, standardized radiographs were not taken, because the study material was submitted by different dental clinics, and the assessment of root length and shape, as well as of crown size and shape, is therefore open to discussion. A considerably higher frequency of root deflections was observed in the dentition. This was seen in the premolar region in the maxilla in 37 per cent of the patients. In comparison, the occurrence in a normal population is 11.8 per cent (Schulze, 1987). Similarly, a very high frequency of invaginations was registered in the upper anterior region, namely 37 per cent, compared with the normal 3–10 per cent (Gorlin and Goldman, 1970). The occurrence of taurodontic permanent upper second molars was likewise

remarkably great, 37 per cent compared with the normal 1.4–5.8 per cent (Schulze, 1987). It is known that taurodontism occurs together with other dental anomalies (Stoy, 1960; Stenvik *et al.*, 1972; Jørgensen, 1982; Schulze, 1987; Kjær, 1995).

Kjær (1995) and other authors (Lind, 1972; Newman, 1975; Levander and Malmgren, 1988; Linge and Linge, 1991) have shown that there is a greater occurrence of dental anomalies in patients with an increased risk of root resorption in connection with orthodontic treatment. It is conceivable that an association exists between dental morphological deviations and malfunction of the periodontal membrane, such as arrested tooth formation and tooth eruption. This agrees with the findings of Bang *et al.* (1995).

The study shows that in patients with arrested eruption of M_2inf morphological anomalies in the dentition occur more frequently than in other dentitions. However, it should be borne in mind that the study group consisted in part of patients who required orthodontic treatment, and it is probably in this group of patients that there is a higher occurrence of dentitional anomalies.

It is remarkable that all patients in the study group had the germ of the third permanent molar, which is normally only seen in 63.4–77.5 per cent (Gorlin and Goldman, 1970). This finding agrees with the observations of Varpio and Wellfelt (1988). This presence of the third molars results in some unanswered questions:

1. Is the third molar responsible for the lack of space for M_2inf ?
2. Can the presence of the third molar influence the prediction of the retention of M_2inf ?
3. Is there a relationship between the mineralization stage of M_2inf and that of the third molar, and is there a connection between the mineralization stages and general skeletal maturity?

Svendsen and Björk (1988) have studied the retention of the lower third molar and demonstrated an association between retention and early general skeletal maturity assessed on hand radiographs. An association was also described between retention of lower third molars and late mineralization of the tooth. To answer these

questions a larger sample of patients with longitudinal radiographs should be available.

Evans (1988), and Varpio and Wellfelt (1988) found a connection between the retention of M_2inf and the occurrence of crowding, both generally in the mandible and locally in the molar region. In the present study it was difficult from the material available to judge dental alignment. Therefore, an estimate of crowding was not included in the analysis.

Of the 19 patients, five did not receive orthodontic treatment. Crowding could be one of the indications for treatment in the 14 patients treated. One could also envisage that in some cases an original lack of space in the anterior region of the dentition was 'displaced' posteriorly in the dental arch in connection with orthodontic treatment.

Evans (1988) concluded that there was a connection between impaction of M_2inf and the degree of mesial inclination. Varpio and Wellfelt (1988) found that most of the impacted teeth were in a mesio-angular position, and that the molars positioned vertically were probably ankylosed. In the present study the majority of the molars with arrested eruption were positioned vertically, and in three of the teeth ankylosis could be demonstrated radiographically and/or clinically. However, according to Raghoobar *et al.* (1989), it is not possible to diagnose ankylosis with certainty clinically, but only histologically.

Relationships between dental anomalies and craniofacial morphology have previously been described, for example in patients with multiple developmentally absent teeth, where the absence of 13–21 permanent teeth occurred in patients with a significantly more anteriorly inclined mandible, a reduced vertical jaw relationship, a smaller mandibular jaw angle and a more prognathic mandible than in patients only missing the germs of 5–12 permanent teeth (Nodal *et al.*, 1994).

The present study of eruption disorders of M_2inf suggests that retention of single teeth is not only a local deviation, but probably part of an extended deviant developmental disorder. The aetiology of arrested eruption of M_2inf is not solved, but the study has indicated various associated features which are new observations and which might lead to more precise clarification in the future.

Address for correspondence

Inger Kjær
Department of Orthodontics
School of Dentistry
Faculty of Health Sciences
University of Copenhagen
20 Nørre Allé, DK-2200 Copenhagen N
Denmark

Acknowledgements

This study was supported by grants from the Danish Medical Research Council (grant no. 9601764) and from IMK Almene Fond.

References

- Andreasen F M, Andreasen J O 1985 Diagnosis of luxation injuries. The importance of standardized clinical, radiographic and photographic techniques in clinical investigations. *Endodontics & Dental Traumatology* 1: 160–169
- Bang E, Kjær I, Christensen L R 1995 Etiologic aspects and orthodontic treatment of unilateral localized arrested tooth development combined with hearing loss. *American Journal of Orthodontics and Dentofacial Orthopedics* 108: 154–161
- Björk A 1947 The face in profile. An anthropological X-ray investigation on Swedish children and conscripts. *Svensk Tandläkartidsskrift* 40: suppl 5B
- Björk A 1960 The relationship of the jaws to the cranium. In: Lundström A (ed.) *Introduction to orthodontics*. McGraw-Hill, New York, pp. 104–140
- Björk A 1969 Prediction of mandibular growth rotation. *American Journal of Orthodontics* 55: 585–599
- Björk A, Skieller V 1972 Facial development and tooth eruption. *American Journal of Orthodontics* 62: 339–383
- Björk A, Skieller V 1983 Normal and abnormal growth of the mandible. A synthesis of longitudinal cephalometric implant studies over a period of 25 years. *European Journal of Orthodontics* 5: 1–46
- Blok I 1991 Arvelighed af ansigtsmorfologi. En røntgen-cephalometrisk analyse af kraniofaciale mål hos pubertetsdrengene med anteriort inklinerede kæber og deres forældre. [Inheritance of facial morphology. A radiographic cephalometric analysis of craniofacial measurements in adolescent boys with anteriorly inclined mandibles and their parents.] Thesis, Royal Dental College, Copenhagen
- Evans R 1988 Incidence of lower second permanent molar impaction. *British Journal of Orthodontics* 15: 199–203
- Gorlin R J, Goldman H M 1970 Thoma's oral pathology, 6th edn. C.V. Mosby & Co., St Louis, pp. 103–109, 124–125
- Grover P S, Lorton L 1985 The incidence of unerupted permanent teeth and related clinical cases. *Oral Surgery, Oral Medicine, Oral Pathology* 59: 420–425
- Jakobsson R, Lind V 1973 Variation in root length of the permanent maxillary central incisor. *Scandinavian Journal of Dental Research* 81: 335–338
- Johnsen D C 1977 Prevalence of delayed emergence of permanent teeth as a result of local factors. *Journal of the American Dental Association* 94: 100–106
- Jørgensen R J 1982 The conditions manifesting taurodontism. *American Journal of Medical Genetics* 11: 435–442
- Kjær I 1995 Morphological characteristics of dentitions developing excessive root resorption during orthodontic treatment. *European Journal of Orthodontics* 16: 25–34
- Levander E, Malmgren O 1988 Evaluation of the risk of root resorption during orthodontic treatment: a study of upper incisors. *European Journal of Orthodontics* 10: 30–38
- Lind V 1972 Short root anomaly. *Scandinavian Journal of Dental Research* 80: 85–93
- Linge L, Linge B O 1991 Patient characteristics and treatment variables associated with apical root resorption during orthodontic treatment. *American Journal of Orthodontics and Dentofacial Orthopedics* 99: 35–43
- Newman W G 1975 Possible etiologic factors in external root resorption. *American Journal of Orthodontics* 67: 522–539
- Nodal M, Kjær I, Solow B 1994 Craniofacial morphology in patients with multiple congenitally missing permanent teeth. *European Journal of Orthodontics* 16: 104–109
- Philipsen H P, Thosaporn W, Reichart P A, Grundt G 1992 Odontogenic lesions in opercula of permanent molars delayed in eruption. *Journal of Oral Pathology & Medicine* 21: 38–41
- Raghoobar G M, Boering G, Jansen H W B, Vissink A 1989 Secondary retention of permanent molars: a histologic study. *Journal of Oral Pathology & Medicine* 18: 427–431
- Raghoobar G M, Ten Kate L P, Hazenberg C A M, Boering G, Vissink A 1992 Secondary retention of permanent molars: a report of five families. *Journal of Dentistry* 20: 277–282
- Schulze C 1987 Anomalien und Missbildungen der menschlichen Zähne. Quintessenz Verlags-GmbH, Berlin, pp. 23–230
- Solow B 1966 The pattern of craniofacial associations. *Acta Odontologica Scandinavica* 24: Suppl. 46
- Stenvik A, Zachrisson B U, Svatum B 1972 Taurodontism and concomitant hypodontia in siblings. *Oral Surgery, Oral Medicine, Oral Pathology* 33: 841–845
- Stoy P J 1960 Taurodontism associated with other dental abnormalities. *Dental Practitioner & Dental Record* 10: 202–205
- Svendsen H, Björk A 1988 Third molar impaction—a consequence of late M_3 mineralization and early physical maturity. *European Journal of Orthodontics* 10: 1–12
- Varpio M, Wellfelt B 1988 Disturbed eruption of the lower second molar: clinical appearance, prevalence and etiology. *ASDC Journal of Dentistry for Children* 55: 114–118
- Wellfelt B, Varpio M 1988 Disturbed eruption of the permanent lower second molar: treatment and results. *ASDC Journal of Dentistry for Children* 55: 183–189